

ای نام تو بهترین سرآغاز

Cervical length & cerclage

Dr parichehr pooransari ,perinatologist

Shohada hospital

The American College of Obstetricians and Gynecologists uses ≤ 20 mm in women with no prior spontaneous birth and < 25 mm in women with a prior spontaneous preterm birth at < 34 weeks of gestation

- before 24 weeks, we make the diagnosis of a short cervix when transvaginal ultrasound cervical length is ≤ 25 mm (2nd to 3rd centile), regardless of the population being evaluated (prior preterm birth, no prior preterm birth, twin pregnancy).




- therapeutic interventions (progesterone, cerclage) initiated at this threshold in women with singleton pregnancies with or without a prior spontaneous preterm birth report a 30 to 40 percent reduction in preterm birth compared with no intervention

The background features several sets of curved lines in the top-left and bottom-right corners. Some lines are solid and others are dashed, creating a sense of movement and depth. The main content area is a purple speech bubble shape pointing downwards.

**Society for Maternal-
Fetal Medicine (SMFM)**

- SMFM recommends routine transvaginal ultrasound (TVUS) cervical length screening between 16 and 24 weeks of gestation for women with a singleton pregnancy and history of **prior spontaneous preterm birth.**

- 
- They recommend **not** performing routine cervical length screening for women with a **cervical cerclage, preterm prelabor rupture of membranes, or placenta previa.**
 - They consider screening reasonable for women with a singleton pregnancy and no history of prior spontaneous preterm birth but **have not recommended routine screening for this population.**

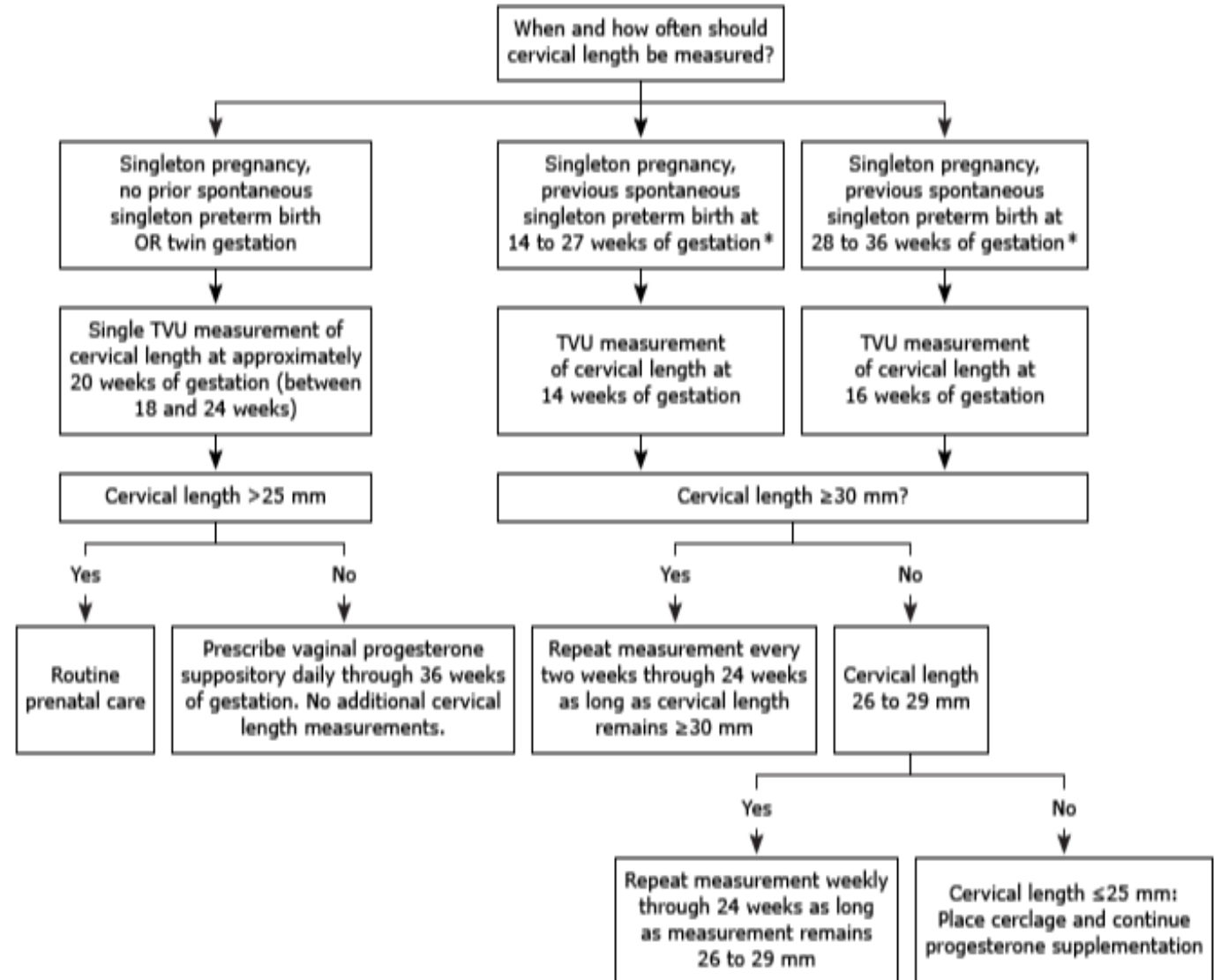
**American College of
Obstetricians and
Gynecologists
(ACOG)**

- ACOG neither mandated universal routine cervical length screening in women without a prior spontaneous preterm birth nor recommended against such screening .
- in women undergoing obstetric ultrasound examination, ACOG has recommended examining the cervix when technically feasible .

**International
Federation of
Gynecology and
Obstetrics (FIGO)**

- – FIGO recommends sonographic cervical length screening in all women 19+0 to 23+6 weeks of gestation using TVU

Approach to transvaginal sonographic screening of cervical length in pregnancy and management of pregnant women with a short cervix



Approximately 1 percent of women
screen positive
(ie, have a short cervix)

- we use the same screening protocol for nulliparous women and parous women with no prior spontaneous preterm birth.

Management of women with a short cervix

- women with risk factors for but no previous preterm birth who have a short cervix in the same way as described above for women without a history of preterm birth who develop a short cervix: treat with vaginal progesterone.

**Parous women
with a prior
spontaneous
twin birth**

- The best approach to women with a prior spontaneous twin birth is controversial.
- The increased risk appears to be limited to previous twin births <34 weeks.

Screening protocol


- **Prior twin spontaneous preterm birth <34 weeks**
- TVUS cervical length screening at 14 to 16 weeks of gestation (the earlier the prior spontaneous preterm birth, the earlier the screening) and perform serial examinations as in singleton pregnancies with a prior preterm birth

Management of women with a short cervix

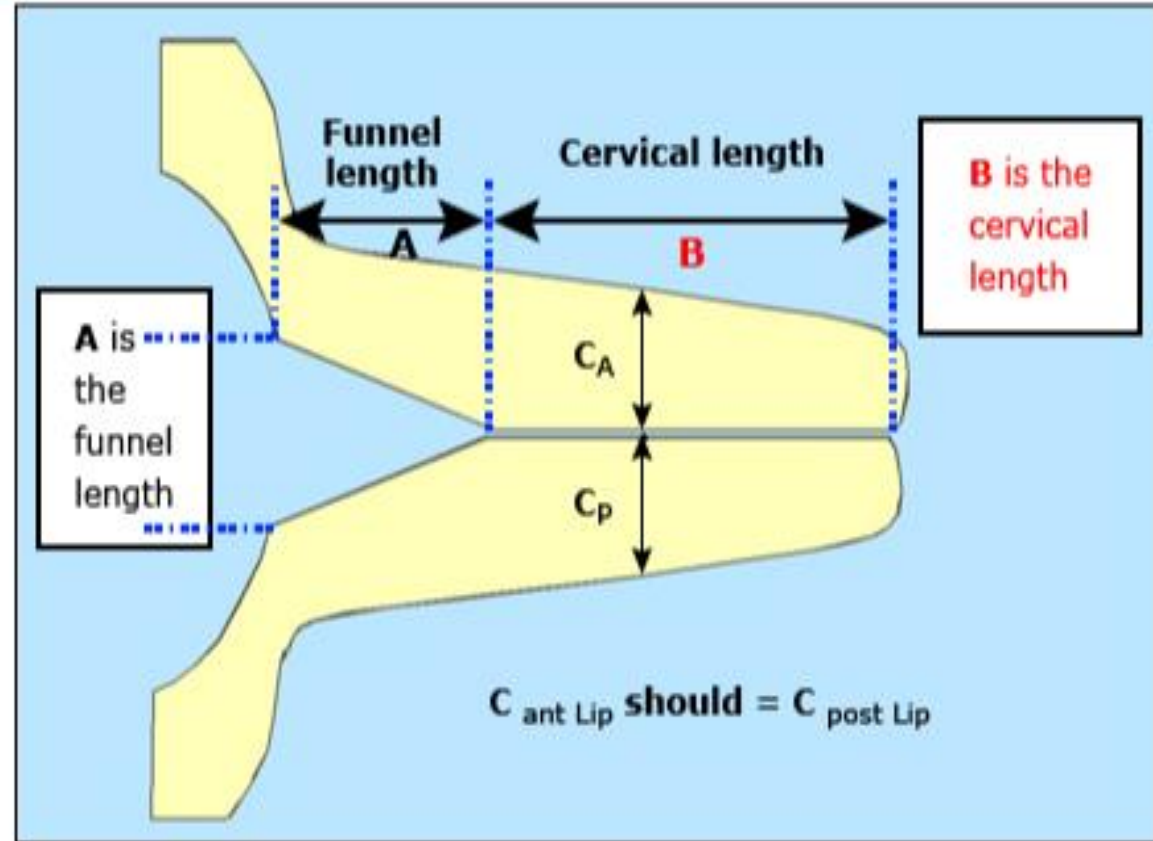
- **Prior twin spontaneous preterm birth ≥ 34 weeks :**
 - vaginal progesterone supplementation upon diagnosis of a short cervix.
- **Prior twin spontaneous preterm birth < 34 weeks** – they are high risk for recurrence offered progesterone supplementation to reduce this risk.
- **If short cervix developed** , offer cerclage in addition to progesterone.

Transabdominal or tvs

- the poorer performance of TAUS has been attributed to multiple factors,
- the bladder often needs to be filled to obtain a good image, resulting in elongation of the cervix and masking of any funneling of the internal os

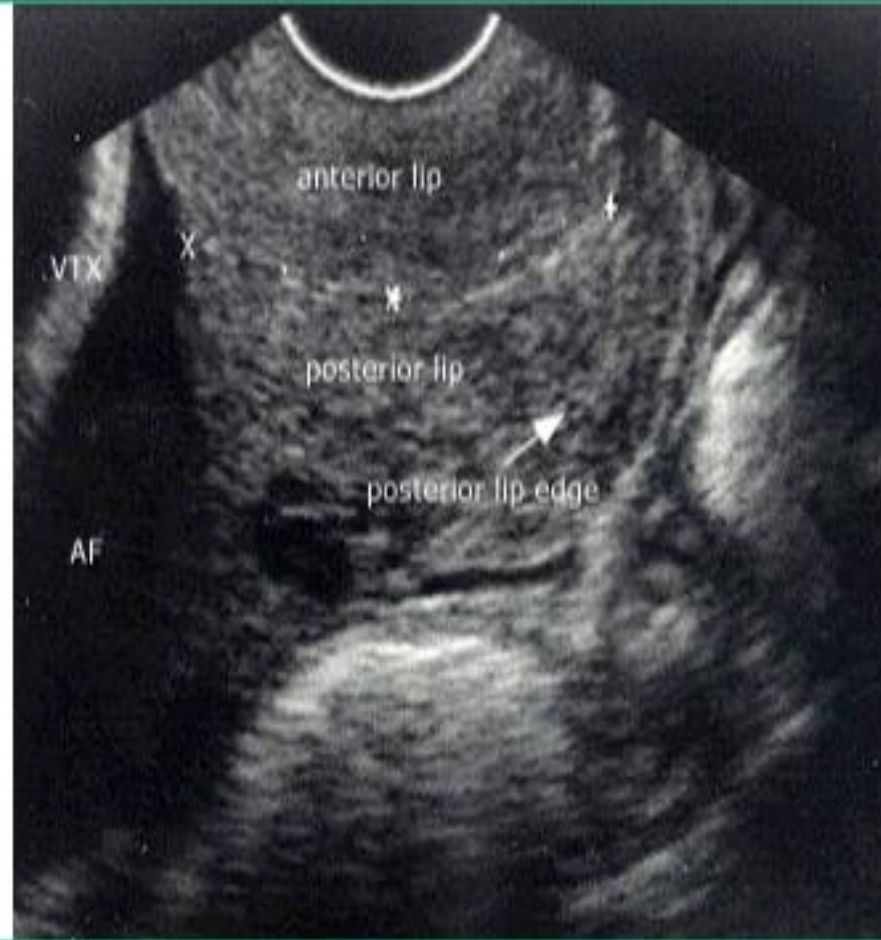
- 
- ; (2) fetal parts can obscure the cervix, especially after 20 weeks;
 - (3) the distance from the probe to the cervix results in degraded image quality; and
 - (4) obesity and manual pressure interfere with the image

Measurement of the cervix



Funnel length should not be measured or recorded as it is not an independent predictor of preterm labor risk when the closed length of the cervical canal is considered.

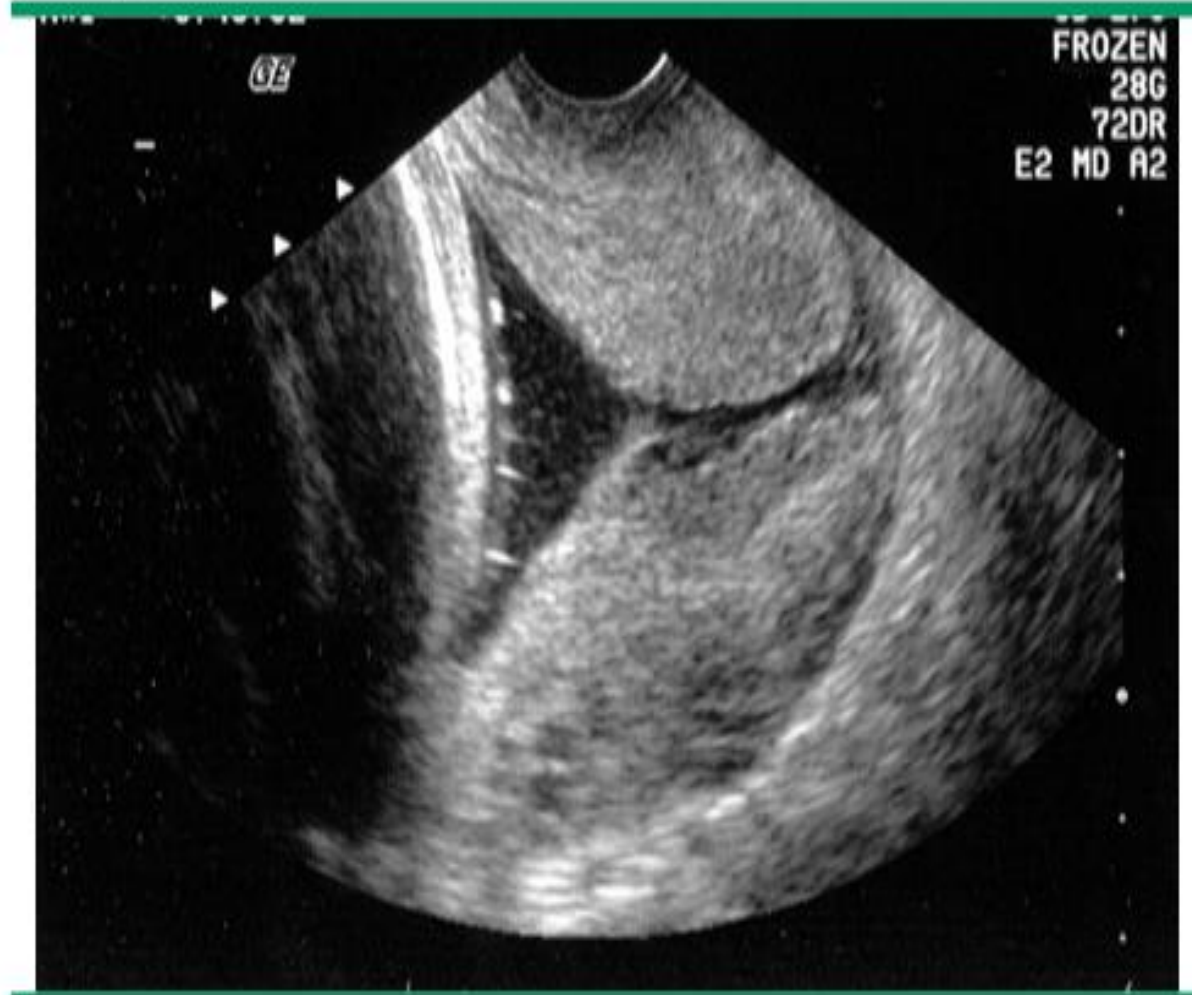Normal cervix



Ultrasound of normal cervix with equal thickness of anterior and posterior cervical lips. X marks the internal cervical os; + marks the external cervical os; the echodense line connecting the two points is the endocervical canal.

AF: amniotic fluid; VTX: fetal head.

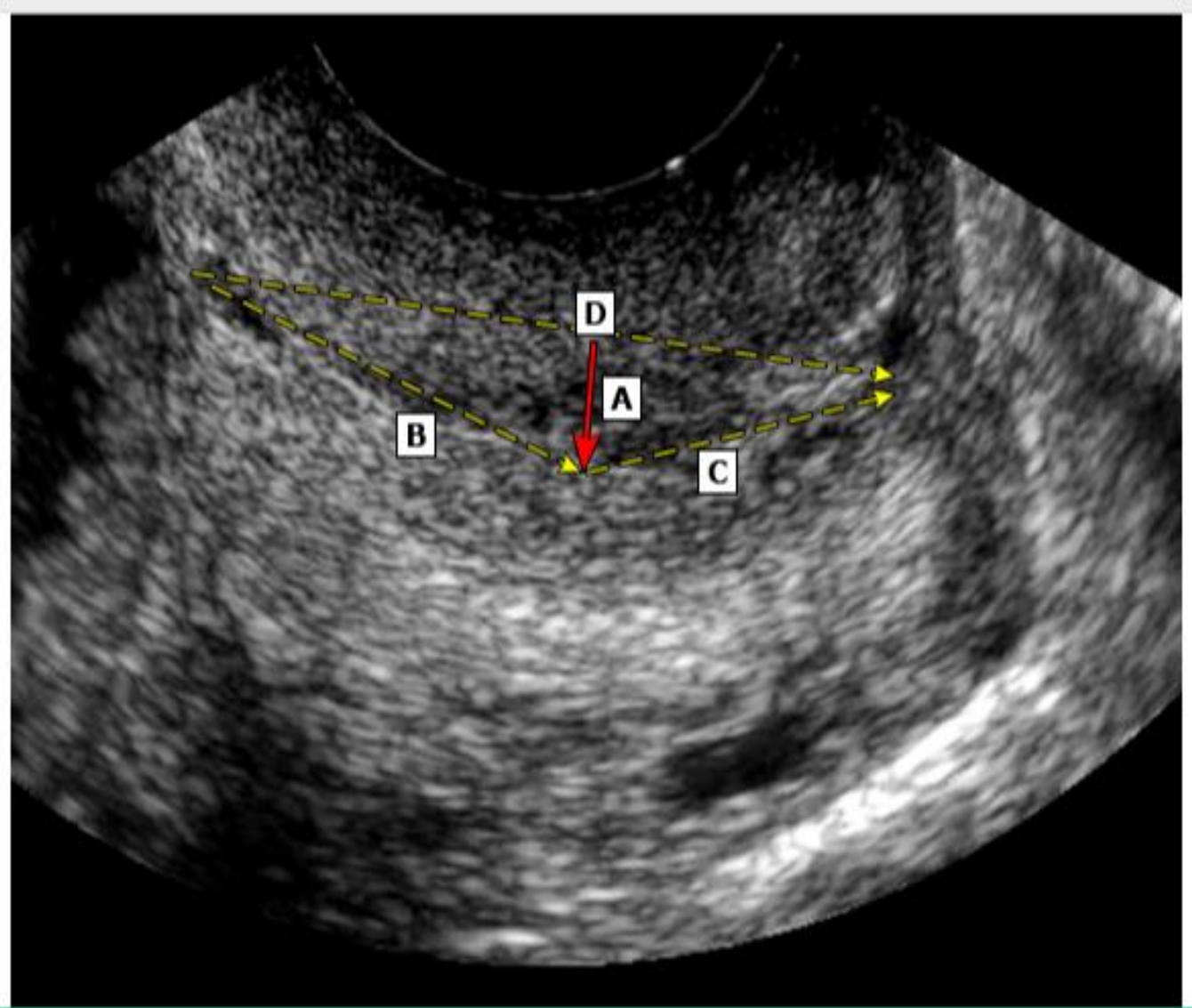
Endovaginal ultrasound image of the cervix in a woman with preterm labor



Courtesy of Jay D Iams, MD.

Graphic 62467 Version 2.0

When three measurements been obtained that satisfy measurement criteria and vary by less than 10 percent, the shortest of these is chosen and recorded as the "shortest best."



Evaluation of cervical length in a patient with a curved cervix. If the widest distance (A, red arrow) between the dashed yellow lines is greater than 5 mm, use the sum of B and C as the best measurement of cervical length. If less than or equal to 5 mm, use D as the best measurement of cervical length.


Transvaginal cervical cerclage

- history-indicated" cerclage, which is best placed at 12 to 14 weeks of gestation
- "ultrasound-indicated" cerclage .(16-23)
- physical examination-indicated" cerclage.(16-23weeks)

Preoperative evaluation

- **Fetal evaluation**
- **Screening for infection**(if they are at high risk of acquiring a sexually transmitted infection)
- before physical examination-indicated cerclage is more controversial
- **Excluding membrane rupture and preterm labor**

- **Antibiotic prophylaxis**

- 
- The American College of Obstetricians and Gynecologists (ACOG) opined that "evidence is insufficient to recommend **antibiotic prophylaxis** for history-, ultrasonography-, or examination-indicated cerclage"

Perioperative tocolytic drugs

- not given to women undergoing placement of a history-indicated cerclage
- indomethacin is commonly prescribed for up to 48 hours in the second trimester, especially in physical examination-indicated procedures
- ultrasound-indicated cerclage, the author restricts indomethacin to patients who have contractions after the surgery.



- **Progesterone**
- **Anesthesia(prefer neuraxial over general anesthesia ,**



- we ask patients to maintain pelvic rest for at least one week after a prophylactic procedure and to use condoms thereafter.

- .



- Women who have had a non-history-indicated cerclage are managed more conservatively;
- physical activity and coitus until a favorable gestational age is reached, usually 32 to 34 weeks of gestation, although there is no high quality evidence that decreasing physical activity improves outcome



[This Photo](#) by Unknown Author is licensed under [CC BY-SA-NC](#)